



**Celebrating 38
Years of Excellence**

U PROSTHETIC & ORTHOTIC UPDATE

A Publication of Nobbe Orthopedics, Inc.

No. 35

Scoliosis—To Brace or Not to Brace?

To enliven an otherwise quiet discourse among orthopedic surgeons, casually drop *orthotic management of scoliosis* into the conversation. You'll generate a spirited difference of opinion in no time.

Adolescent idiopathic scoliosis (AIS) challenges precise management protocols because, as the name explains, its cause is unknown; it is detected at various levels of skeletal maturity; scoliotic curves vary widely in degree, type and location; and image-conscious, active, determined teenagers are not the most compliant patient population to be found.

Nevertheless, the past decade has produced significant progress in research, understanding, treatment options and orthosis designs, so that we have a much more effective range of therapeutic options than in the past. Two of the newer approaches to bracing are discussed on pages 3 and 4.

Despite numerous individual successful outcomes dating back to the early days of the Milwaukee Brace in the mid-1940s,

detractors have long cited the lack of prospective, controlled studies confirming scoliosis bracing success. That deficiency was addressed in 1995 when the results of the Scoliosis Research Society's (SRS) nine-year, prospective multinational trial on bracing effectiveness were published in *The Journal of Bone and Joint Surgery* (Vol. 77-A, No. 6).

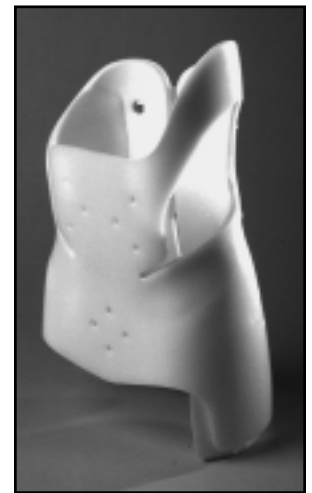Even more problematic was a lack of agreement as to what constitutes success. Though patients generally improved while

undergoing orthotic management, their curves more often than not returned upon cessation of brace therapy.

"What good is that?" asked bracing opponents.

"Well," the proponents countered, "we stopped the curve progression until the patient reached skeletal maturity and thereby precluded the need for spinal fusion or other major surgery."

Indeed, the generally accepted object of scoliosis bracing today is to prevent further progression of the curve until the patient achieves skeletal maturity and yield a post-bracing curve that will not progress further in adulthood. Some patients actually do experience some permanent curve reduction upon completion of bracing, which can be regarded as a bonus. Others experience further curve progression and may need surgery.



Boston Brace TLSO

Scoliosis Management

(Continued on page 2)

Now Serving Lompoc Valley

We are pleased to announce that Nobbe Orthopedics now offers orthotic and prosthetic appointment hours in Lompoc Valley on Tuesday mornings and Friday afternoons. We see patients in Lompoc by appointment only.

Bob Nye, RPT, director of Nye Physical Therapy, is providing us use of his well-equipped facility for evaluations, fittings, follow-up and minor adjustments. The facility is centrally located and offers ample parking and easy wheelchair access.

The Nye Therapy staff is most helpful but will not be able to schedule appointments, answer questions or otherwise assist you on our behalf. All Nobbe Orthopedics administrative functions, scheduling and record-storage continue to be handled by our Santa Barbara (805-687-7508) and Santa Maria (805-925-8290) offices.

Our Lompoc location: **Nye Physical Therapy**
1101 E. Ocean Ave.
Lompoc, CA 93436

When Is Spinal Bracing for Scolio

(Continued from page 1)

Though 2-4% of adolescents have scoliosis to some degree, only 10% of those require intervention. Most of the remainder will reach skeletal maturity (and curve stability) before their curvature exceeds 25° Cobb angle, the widely accepted bracing threshold.

Another key factor in the To Brace or Not to Brace decision is the likelihood of curve progression. Significant curve progression is most likely:

- in higher-level (i.e. thoracic) curves;
- in adolescent females (a 10 times greater risk than adolescent males); and
- in patients with larger curves before reaching their adolescent growth spurt.

Untreated curves above 20° can be expected to progress during adolescence. Curves above 45° will likely continue to progress in adulthood and are generally managed surgically.

Once curve progression above 20° is deemed likely, the sooner bracing begins, the better the anticipated results. Research has

shown that for a bracing protocol to be effective, the orthosis should produce at least a 50% in-brace correction.

Biomechanically, a conventional scoliosis orthosis counters spinal curvature through a system of pads that apply indirect forces to the curves' apex by pushing on ribs in the thoracic spine and muscles in the lumbar region. The pads are anchored by a rigid thermoplastic shell or metal frame.

Equally important as the proper application of corrective pressure through optimal placement of the corrective pads is ensuring that the brace provides adequate clearance for growth, unrestricted pulmonary expansion and unimpeded renal function.

For every scoliosis patient entrusted to our care, our orthotic staff works with physician, patient and family to ensure that:

(1) each orthosis we design is constructed for optimal corrective force application and accommodation for normal body functions, growth and development;

(2) patient and family understand completely how the brace works and the necessity for adherence to the prescribed wearing schedule. (With the exception of nocturnal recumbent orthoses, scoliosis braces are intended to be worn 16 or more hours a day with breaks for bathing and participation in sports activities.)

(3) the orthosis is constructed to provide maximum possible comfort and least possible impact on the patient's self-image and social quality of life.

Selecting the Best Design

Excepting certain newer designs whose long-term merits are still being ascertained, contemporary scoliosis braces fall into one of three categories:

TLSO—The thoracolumbosacral orthosis, also called an “under-arm” brace, is typically constructed of rigid thermoplastic and is usually capable of being worn inconspicuously under clothing. It is generally prescribed for single and double curves of the thoracolum-

bar and lumbar spine and is by far the most-prescribed scoliosis design in the U.S.

Of the TLSOs, the Boston Brace, a prefabricated product available in various sizes and allowing custom trimlines and pad placement at the orthotist's discretion, is most commonly used. Other TLSO designs that have enjoyed some measure of popularity in recent years include the Miami, Wilmington and Rosenberger orthoses.

CTLSO—The oldest living scoliosis design, and generally the least-liked by wearers, is the tried-and-true Milwaukee cervicothoracolumbosacral orthosis, which made its debut more than a half-century ago. Throughout the intervening decades, youthful wearers—to whom appearance and conformity are vital to social acceptance and self-esteem—have long disliked the Milwaukee for its distinctive neck ring and external frame.

Not surprisingly, compliance is a major problem, which is unfortunate because the Milwaukee has turned in impressive results when patients can be induced to wear it as prescribed. Moreover, it is widely regarded as the only effective brace for limiting curve progression in patients with high thoracic curves (T7 and up). Thus, variations on the basic Milwaukee design can still be found in use today.

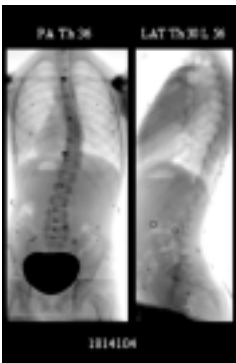
Nocturnal orthoses—The theory behind the Charleston Bending Brace and newer Providence Scoliosis System (see page 3) is that a hypercorrective force applied for a shorter period (nominally eight hours while sleeping), can be as effective in preventing curve progression as wearing a TLSO or CTLSO. At a minimum, this approach offers a viable option for image-conscious patients who absolutely refuse to wear a daytime brace. Other recognized benefits include less sleep disturbance and back pain and greater back flexibility and improved body image.

Studies of Charleston brace effectiveness over the past 15 years have led to a growing consensus that the orthosis can be effective in well-chosen patients with smaller (i.e. less than 35°) single curves. Recent research into the newer Providence Brace suggests that it may be more effective in correcting double and higher curves as well.

Why Bracing Sometimes Doesn't Work

Reasons for bracing failure include:

- High thoracic curves. Curves above T7 are particularly difficult.
- The male gender. Scoliosis occurs more than five times as frequently in girls as in boys. Girls also experience much higher success rates from bracing. This is not to say boys with scoliosis cannot be helped by bracing, but the effort is usually more challenging.
- Poor compliance. Regardless of gender, wearing a rigid spinal orthosis, is definitely not cool, in terms of either body temperature or social acceptance. The most exacting brace we can design will render no viable results if not worn according to the prescribed schedule,



Scoliotic curve



Milwaukee-style brace with neck ring

osis Appropriate?

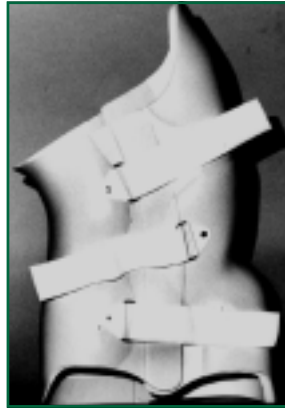normally from 16 or more hours per day. All that said, bracing can help a significant percentage of AIS patients, notably those who understand and follow prescribed wear guidelines.

Once initiated, the bracing protocol should be continued until either the patient achieves skeletal maturity, as indicated by Risser level 4 or 5, and in girls 18 months after menarche—or curvature increases to 45-50°, indicating the need for surgery.

Our orthotic staff is prepared to work with physicians, patients and families to determine and deliver the best orthotic approach to each scoliosis situation.

We recognize that each patient presents a unique orthotic challenge and that nothing less than a fully individualized treatment plan will yield the best chance for a successful outcome.

We welcome your questions, comments, requests for further information and referrals.



*Charleston Bending
Brace*

Prescription Notes

Given that each physician's approach to managing AIS is unique and that prescription patterns tend to vary by region, the following general considerations may prove helpful in developing a treatment plan:

- Curves of less than 20° are usually left unbraced and monitored closely for progression.
- AIS patients with curves between 20° and 30° and progressing are candidates for bracing.
- Skeletally immature patients with curves between 30° and 45°, whether progressing or not, are generally treated with an orthosis.
- Curves above 45° will generally not benefit from bracing. Surgery is generally indicated.
- Higher level thoracic curves (T7 and above) may best be managed with a Milwaukee-type TLSO.
- Upon commencement of bracing, patients should be seen by their orthotist at least every four months for evaluation of progress and growth adjustments.

A Boost for Nighttime Scoliosis Bracing

The Providence Scoliosis System is a second-generation recumbent nighttime bracing approach to conservative scoliosis management, following the pioneer Charleston Bending Brace.

Compared with conventional braces, these orthoses are designed to deliver a large in-brace correction over a shorter period of time...i.e. when sleeping. When this approach works, the obvious advantage is that patients are free from the physical restrictions and psycho-social trauma of wearing a TLSO or Milwaukee-type brace through adolescence.

Unlike the Charleston design, which functions by bending the spine, the Providence brace applies controlled direct lateral and rotational forces on the trunk, resulting in greater in-brace corrections than various other methods. The Charleston brace has been shown effective in halting the progression of single lumbar curves of 35° and less; in patients with double curves, however, it can actually worsen the secondary curve. The Providence brace, which is fabricated with the aid of CAD-CAM technology, purportedly is valid for treating a wider range of curves, including double curves.


The Brown University School of Medicine Department of Orthopaedic Surgery recently reported on the results of its seven-year prospective study of 102 consecutive female AIS patients, (age 10-16, Risser 0, 1 and 2), treated with the Providence brace. Results were published in the Sept. 15, 2001 issue of *Spine* (Vol. 26, No. 18). The study included compliant and non-compliant patients.

From 1992 to 1999, all 102 patients completed treatment and were followed for a minimum of two years after cessation of bracing.

Curves between 20° and 42° were included. Patients were directed to wear the brace nightly for eight hours, and to continue until 18 months after attaining regular menses.

Study results are encouraging for further use of the Providence system and nighttime bracing:

- Initial in-brace correction of major and compensatory curves averaged 96% and 98% (Cobb angle) respectively.



Providence brace

Research Report

- Bracing was successful for 74% of the subjects, defined as curve progression of $\leq 5^\circ$ before reaching spinal maturity. The remaining 26% experienced $\geq 6^\circ$ progression and/or moved on to spinal fusion surgery.

- 76% of patients with curve apexes between L1 and T8 had successful results, closely comparable to the 74% of TLSO-managed patients in the major Scoliosis Research Society trial, who had successful outcomes wearing the brace 16 or more hours a day.

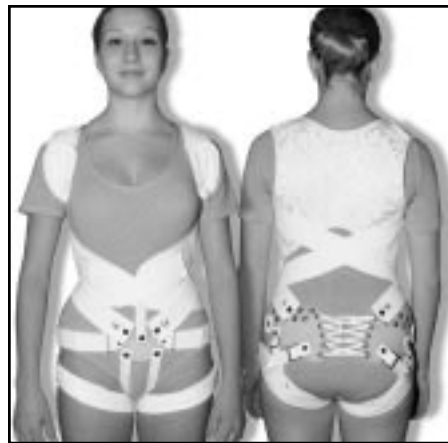
- Perhaps most noteworthy, the Providence orthosis produced a successful outcome in 63% of patients with thoracic curves and 65% of those with double curves. The success rate increased to 93% for thoracolumbar curves and 94% for lumbar curves.

This study suggests that nighttime bracing with the Providence brace can be effective for a wider range of curves than with previous nighttime-only orthoses and can approach or match the effectiveness of standing braces in many patients.

SpineCor—A Different Scoliosis Approach

As noted throughout this issue, mainstream orthotic management of scoliosis, whether following an all-day or night-only protocol, involves a rigid, usually thermoplastic, spinal brace whose purpose is to prevent further progression of scoliotic curves until the patient reaches skeletal maturity.

A relatively new alternative method now attracting attention in the orthopaedic community replaces the rigid TLSO or CTLSO frame with a free-moving configuration of belts, straps and pads fixed at



one end to a plastic pelvic base and at the other by a cotton “bolero” or vest. If this “dynamic strapping orthosis,” marketed under the name SpineCor, proves viable over the long term, the advantages of increased comfort, freedom and cosmesis likely will make it a popular treatment option in future years.

The SpineCor system is based on a strategy of

postural reorganization to achieve progressive curve correction. Four adjustable elastic bands work together to maintain and improve spinal deformity while re-educating the body to return to a more normal posture. Band configuration and lengths are determined with the aid of software that monitors clinical, radiological and postural variables, classifies the curve pattern and describes the specific corrective movement strategy for that curve type.

For example, a “Right Thoracic, Type I” curve is managed with counterclockwise rotation of the thorax and clockwise rotation of the shoulder girdle. The classification system includes 10 basic curve patterns, each of which can have a reverse variant, making a total of 20 possible types.

Other claimed benefits of the SpineCor system include a lack of

abdominal muscular atrophy, which typically accompanies rigid bracing... patients’ ability to spend four hours each day out of the brace... absence of adverse developmental side effects... and a significant incidence of sustained curve reduction post-bracing.

The SpineCor’s developers recommend the orthosis for AIS curves of 15°-50° and suspected high risk of progression or observed increase of $\geq 5^\circ$ within six months. Like traditional rigid orthoses, the best results occur among skeletally immature patients with curvatures of less than 30°.

Initial results of the SpineCor system are encouraging. Of 765 patients treated worldwide and reported to the developer’s central database, 57% have maintained a reduction of curvature, 32% report their curve stabilized at skeletal maturity, and 11% have experienced a curve progression of 5° or more.

Further treatment results will be reported in forthcoming articles accepted for publication by the Scoliosis Research Society and *European Spine Journal*.

**What's
New**

Note to Our Readers

Mention of specific products in our newsletter neither constitutes endorsement nor implies that we will recommend selection of those particular products for use with any particular patient or application. We offer this information to enhance professional and individual understanding of the orthotic and prosthetic disciplines and the experience and capabilities of our practice.

We gratefully acknowledge the assistance of the following resources used in compiling this issue:

***Boston Brace International Inc. • The Spine Corporation Ltd.
Charleston Bending Brace Research & Education Foundation
Scoliosis Research Society • Spinal Technology Inc.***

PROSTHETIC & ORTHOTIC UPDATE

A Publication of
Nobbe Orthopedics, Inc.

3010 State Street
Santa Barbara, CA 93105
(805) 687-7508
FAX (805) 687-6251

203 East Fesler
Santa Maria, CA 93454
(805) 925-8290
FAX (805) 346-8713

1101 E. Ocean Ave.
Lompoc, CA 93436

All contents copyright 2002

Nobbe Orthopedics, Inc.

3010 State St. • Santa Barbara, CA 93105